

See discussions, stats, and author profiles for this publication at: <https://www.researchgate.net/publication/304397709>

# Modern Endodontic Principles Part 5: Obturation

Article *in* Dental update · March 2016

CITATIONS

0

READS

235

5 authors, including:



[James Darcey](#)

The University of Manchester

23 PUBLICATIONS 99 CITATIONS

[SEE PROFILE](#)



[Reza Vahid Roudsari](#)

The University of Manchester

16 PUBLICATIONS 26 CITATIONS

[SEE PROFILE](#)



[Carly Taylor](#)

The University of Manchester

17 PUBLICATIONS 14 CITATIONS

[SEE PROFILE](#)

Some of the authors of this publication are also working on these related projects:



Modern Endodontics [View project](#)



Prediction of competency in longitudinal observations [View project](#)

All content following this page was uploaded by [James Darcey](#) on 25 June 2016.

The user has requested enhancement of the downloaded file. All in-text references [underlined in blue](#) are added to the original document and are linked to publications on ResearchGate, letting you access and read them immediately.



James Darcey

Reza Vahid Roudsari, Sarra Jawad, Carly Taylor and Mark Hunter

# Modern Endodontic Principles Part 5: Obturation

**Abstract:** Once cleaning and shaping is complete the clinician must obturate the canal. There are many different materials and techniques available each with their own discrete advantages and disadvantages. Whichever technique is used, the goal is to seal the entire prepared length of the root canal. This paper describes how best this may be achieved.

**CPD/Clinical Relevance:** It is incumbent on the clinician to ensure that once the canal has been prepared it is sealed from bacterial re-entry.

**Dent Update 2016; 43: 114–129**

The purpose of obturation is to seal the cleaned, shaped and disinfected root canal system and to prevent re-infection. It is now well understood that teeth that are poorly obturated are often poorly prepared.<sup>1</sup> When

assessing obturated roots, it has been shown that obturation without voids and to within 2.0 mm of the apex has a significant positive influence on the outcome of treatment.<sup>2</sup> It has been emphasized that good obturation should create a good seal; this includes apical and coronal seal as well as lateral seal. There have been several materials and techniques developed to achieve this; however, all the materials and techniques are believed to show evidence of leakage to some degree.<sup>3</sup>

## Ideal properties of obturation materials

Many materials and techniques are available to obturate the root canal system. Grossman *et al* have described the properties of an ideal obturation material (Table 1),<sup>4</sup> however, no single material can currently satisfy all these requirements. As such, practitioners are dependent upon a combination of sealer and some type of core material to ensure optimal obturation.

## Types of sealers

Sealers are a necessary part of the obturation process. They fill in the gap between the dentinal wall and the core root filling material as well as the space between the core segments, if applicable. They are also

able to fill in irregularities within the canal system and are able to occlude accessory canals as well as isthmi between canals. Grossman has described the properties of an ideal sealer material (Table 2). Again, no such material exists as yet but many forms of sealer are marketed, each with specific pros and cons (Table 3).

## Core materials

A variety of core materials exist which can be used in conjunction with a sealer or cement (Table 4).

## Gutta-percha

Gutta-percha (GP) is the most common core material used for obturation. GP cones are available in standardized and non-standardized (conventional) sizes. The non-standard nomenclature refers to the dimension of the tip and body; for example a fine medium (F-M) cone has a fine tip and a medium body. The standardized cones match the taper of the nickel-titanium and stainless steel instruments; for example, a size 30/06 cone has a tip of 0.3 mm and a taper of 0.06mm per millimetre. Any method of heating GP will result in 1–2% shrinkage of the core material. Exposure to air and light over time can result in the GP becoming


**James Darcey**, BDS, MSc, MDPH, MFGDP, MEndo, FDS Rest Dent, Consultant and Honorary Lecturer in Restorative Dentistry, University Dental Hospital of Manchester, **Reza Vahid Roudsari**, DDS, MFDS, MSc, PGCert, Clinical Lecturer/Honorary Specialty Registrar in Restorative Dentistry, Dental School, University of Manchester, **Sarra Jawad**, BDS, BSc, MFDS, Specialty Registrar/Honorary Clinical Lecturer in Restorative Dentistry, University Dental Hospital of Manchester, **Carly Taylor**, BDS, MSc, MFGDP, FHEA, Clinical Lecturer/Honorary Specialty Registrar in Restorative Dentistry, Dental School, University of Manchester and **Mark Hunter**, BDS MSc, Registered Endodontic Specialist, simplyendo, Altrincham, Postgraduate Clinical Teaching Fellow, Dental School, University of Manchester, Manchester, UK.

Easily introduced into the root canal system	Should seal the canal laterally as well as apically
Should not shrink after being inserted	Should be impervious to moisture
Should be bacteriostatic or at least not encourage bacterial growth	Should be radio-opaque
Should not stain tooth structure	Should not irritate periapical tissue
Should be sterile or easily and quickly sterilized immediately before insertion	Should be easily removed from the root canal if necessary

**Table 1.** Ideal properties of an obturation material.<sup>4</sup>

Should exhibit tackiness when mixed to provide good adhesion to the canal wall when set	Should establish a hermetic seal
Should be radio-opaque	Should be prepared in very fine powder so it can mix with liquid easily
Should not shrink on setting	Should not stain tooth structure
Should be bacteriostatic or at least not encourage bacterial growth	Should exhibit a slow set
Should not be soluble in tissue fluids	Should not irritate periapical tissue
Should be soluble in a common solvent if it is necessary to remove it	

**Table 2.** Ideal properties of a sealer.<sup>4</sup>



**Figure 1.** (a) Standard ISO 2% taper 0.2 mm GP. (b) Greater taper 7% apical taper 0.2 mm GP with variable taper for use with *ProTaper* (Dentsply, Tulsa, USA). (c) Non-standardized GP medium accessory point.



**Figure 2.** Resilon points. These have similar handling properties to GP and are size-matched to multiple filing systems.

brittle. Storage in the fridge extends the shelf-life of the material (Figure 1).

### Coated cones

These core materials consist of GP coated with resin (*EndoREZ*), chlorhexidine or glass ionomer (*Activ GP Plus*). A single cone is used with the matching sealer with an aim to form a bond between the core material and the canal wall to reduce microleakage.

### Resilon

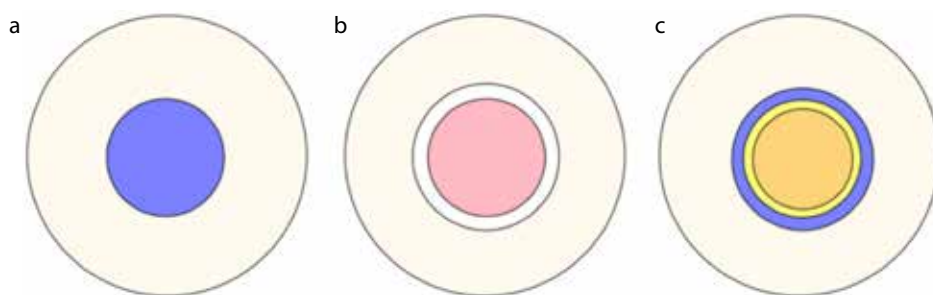
Resilon is a high-performance industrial polycaprolactone polyester that has been adapted for dental use to replace GP. *Epiphany*, *RealSeal* and *Resinate* claim that their resin-based sealer systems bond to the canal wall as well as the Resilon core to form a monoblock (see below). Resilon resembles GP and is available in standardized (2% taper) and non-standardized cones, as well as in pellet form for use in an 'Obtura' gun (a thermal injection technique). It can be placed using lateral compaction, warm lateral or vertical compaction or thermoplastic injection techniques. Sodium hypochlorite can adversely affect the bond strength of the primer; therefore, EDTA should be the last irrigant used before rinsing the canal with sterile water, saline or chlorhexidine. Once the canal is dried, the self-etching primer is applied and the excess is removed. The resin sealer is then mixed and applied to the working length (WL) before the canal is obturated with Resilon. It is recommended to light-cure the coronal section for 40 seconds as the sealer takes 25 minutes to set (Figure 2). The evidence supporting the use of Resilon is inconclusive. Laboratory-based tests comparing Resilon to conventional GP for lateral canal sealing, bond strength to root canals and sealing ability are equivocal.<sup>5</sup>

### Pro-Points

Pro-Points (EndoTechnologies, LLC, Shrewsbury, MA) are a new 'smart sealing' system. They consist of a nylon polymer core with a hydrophilic polymer coating. They are used in conjunction with a hydrophilic MTA-based sealer (*SmartPasteBio*, EndoTechnologies, LLC, Shrewsbury, MA). The points undergo hygroscopic expansion within the canal to fill voids. The polymer and sealer are theoretically expressed into dentinal tubules and form a seal that is resistant

Type of the sealer	Example	Pros	Cons
Zinc oxide and eugenol	Pulp Canal Sealer EWT Roth's Sealer Tubli-Seal Wach's Sealer	Long history of use Will absorb if extruded Slow setting time Antimicrobial effect Radio-opaque	Shrinkage on setting Soluble Can stain tooth structure May negatively affect bonding of core materials
Calcium hydroxide	Apexit Apexit Plus Sealapex	Antimicrobial effect (unproven) Radio-opaque	Soluble May weaken dentine
Glass ionomer	Activ GP Ketac-Endo	Dentine-bonding properties No antimicrobial properties	Hard to remove in retreatment Minimal antimicrobial effect
Resin	AH-26 AH Plus Diaket EndoREZ Epiphany RealSeal	Long history of use Adhere to the wall Some can adhere to the core Do not contain eugenol Slow set	Some release formaldehyde when setting Chlorhexidine as an irrigant can reduce their bond strength May not bond any more effectively than conventional sealers
Silicone	GuttaFlow RoekoSeal	Triturated Long working time Fills canal irregularities with consistency Biocompatible	Expand slightly on setting Setting time is inconsistent Setting time gets delayed by sodium hypochlorite
Bioceramic	SmartSeal SmartPaste Bio	Hydrophilic Does not shrink on setting Biocompatible Antimicrobial properties	Minimal supporting clinical data Questions raised over ease of removal for retreatment

**Table 3.** Advantages and disadvantages of differing commercially available sealers.



**Figure 3.** The 'monoblock' concept. **(a)** A primary monoblock has one interface, eg composite core; **(b)** a secondary has two interfaces, eg GP and sealer and **(c)** a tertiary monoblock has three interfaces, eg post silane coupling layer and resin cement.

bonds to dentine and forms a homogeneous mass or 'monoblock' within the canal. Different types of monoblock have been described based upon the number of interfaces between core materials, sealers and the root canal walls. A primary monoblock has one interface: that with the canal wall. A canal filled with MTA may be said to have a primary monoblock. A secondary has two interfaces, such as the use of a sealer and core material. A tertiary monoblock has three interfaces; classically a bonded post:

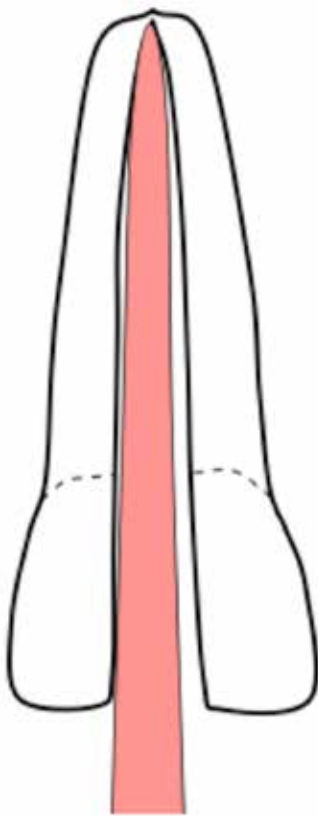
1. A cement interface with the canal;
2. An interface with a surface coating of the post itself to allow adhesion; and
3. An interface with the coating and the post (Figure 3).

Though conceptually appealing,

to micro leakage.<sup>6</sup> There is as yet minimal laboratory or clinical evidence to substantiate these claims.

### The 'monoblock' concept

This concept is borne from the desire to place a root-filling material that



**Figure 4.** Single point obturation. Voids around the GP necessitate a greater dependency on sealer.

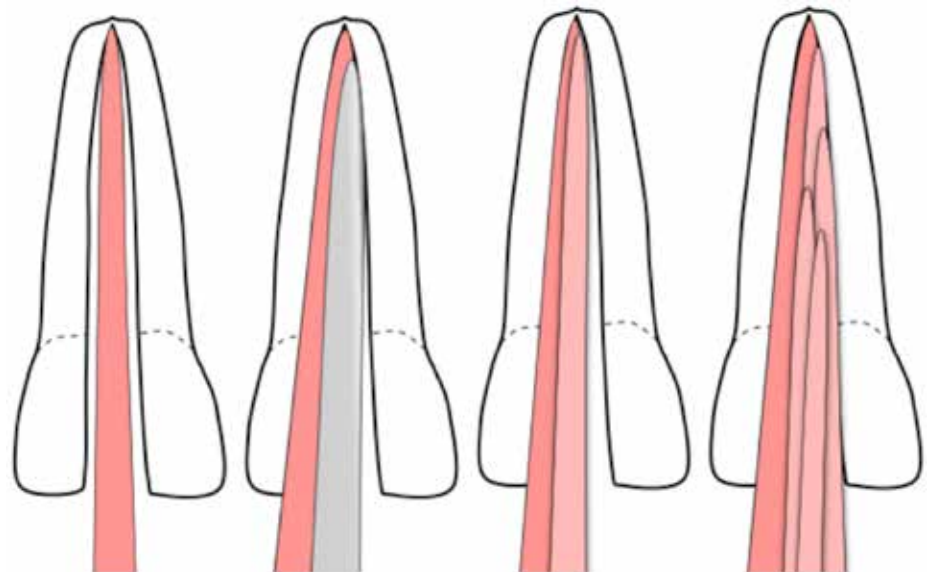
the concept of bonding to the root canal structure is fraught with difficulty and as yet an ideal material to achieve this does not exist.<sup>7</sup>

### Obturation techniques

Several obturation techniques exist with little difference in their long-term outcome results and there is no technique that prevents leakage.<sup>8,9</sup> There is some evidence to suggest that warm vertical compaction is superior to lateral compaction.<sup>10,11</sup>

#### Single cone technique

This refers to the use of a size-matched greater taper cone to fit the preparation of the canal precisely. Such an approach is often used in conjunction with specific filling systems. This technique is often reliant upon sealer and may not adequately obturate the canal in 3 dimensions. Nonetheless, the apical portion should be



**Figure 5.** Cold lateral compaction following the placement of the master GP point. It is compacted against the canal wall with a spreader. An additional GP point is then placed into the void left by the spreader. The process is repeated until the canal is filled.

Core material	Pros	Cons
Gutta-percha	Plasticity Ease of manipulation Minimal toxicity Radio-opacity Ease of removal with heat or solvent	Lack of adhesion to dentine Shrinkage on cooling when heated
Coated cones	Similar to gutta-percha Adhesion to canal wall	Adhesion is not complete and leakage has been demonstrated
Resilon	Similar to gutta-percha May form a monoblock	Formation of monoblock is controversial
Pro-Points	Expand to fill voids and lateral canals Used with bio-active sealer	Limited evidence on effectiveness

**Table 4.** Advantages and disadvantages of differing core materials.

well fitting. Up to 49% of dentists favour this technique and laboratory evidence suggests that this is comparable to lateral compaction<sup>12,13</sup> (Figure 4).

#### Lateral compaction (cold lateral compaction)<sup>5</sup>

A master cone corresponding to the final working length (FWL) and canal shape is chosen, coated in sealer and compacted laterally with finger spreaders. Accessory cones will be used until the obturation is complete (Figure 5). This

technique does not produce a homogeneous mass and the core material and the accessory cones remain separated. As a result, sealers should be used to fill in the gaps. Excessive force whilst compacting GP may lead to root fracture.<sup>14</sup>

Tips for success include:

- Always ensure a friction fit of the master apical point at the working length to confirm snugness of fit and resistance to displacement during compaction. (This tip applies to all systems using master points.)



- Manufacturing errors in GP points can create significant variation in size. If the point is short or long, always try a second point before doubting your instrumentation. GP size-checkers are handy tools to assess the apical diameter of standardized and non-standardized points. (This tip applies to all systems using master points.) (Figure 6).
- Measure and place a stopper on the spreader to gauge the depth to which the accessory GP point will be placed, ideally the first should be within 1–2 mm of FWL.<sup>15</sup>
- Ensure the accessory cones are matched to (or slightly smaller than) the spreader size (non-standardized accessory cones do not match ISO 0.02 standard taper spreaders and as such accessory points will not seat to the full depth of the space left by the spreader, resulting in possible voids).
- Mark the master cone to ensure it is not

forced beyond or withdrawn from the apex as the spreader is placed and removed.

### Warm vertical compaction<sup>16</sup>

A master cone corresponding to the correct working length and canal size is chosen. The cone should resist displacement at this length. Once confirmed, the cone is coated with sealer and placed in the canal and compacted vertically using a heated plugger until the apical 3–4 mm segment of the canal is filled. The canal system is then backfilled using warm pieces of core material. It is important to check the apical fill radiographically before back filling, otherwise it is costly in terms of time to rectify apically inadequately fills.

A variation of this is the continuous wave compaction technique.<sup>17</sup> It describes a method of warm vertical

compaction when a commercial heating device, such as 'System B' or 'Elements', is used. After fitting an appropriated cone with sealer, the heated plugger is inserted to within 5–7 mm of the working length, either in a continuous 'down-pack' motion or 'down-packing' intermittently. After a 10-second pause, whilst the softened GP is cooling, a separation burst of heat is applied severing the apical GP. The warm GP apical to the point of severance is compacted with a flat-ended plugger and the canal is then 'backfilled' using an injection technique (Figures 7 and 8).

### Warm lateral compaction

A master cone corresponding to the working length and canal shaper is coated with sealer and inserted. A warm spreader or *Endotec II* device is then used to compact the core material laterally. The process is then continued by using the accessory canals and the compaction is repeated. The heat results in adhesion of the accessories to the core material and a more homogeneous mass of GP is produced within the canal. An advantage of this technique over the vertical techniques is the ability to control the working length.

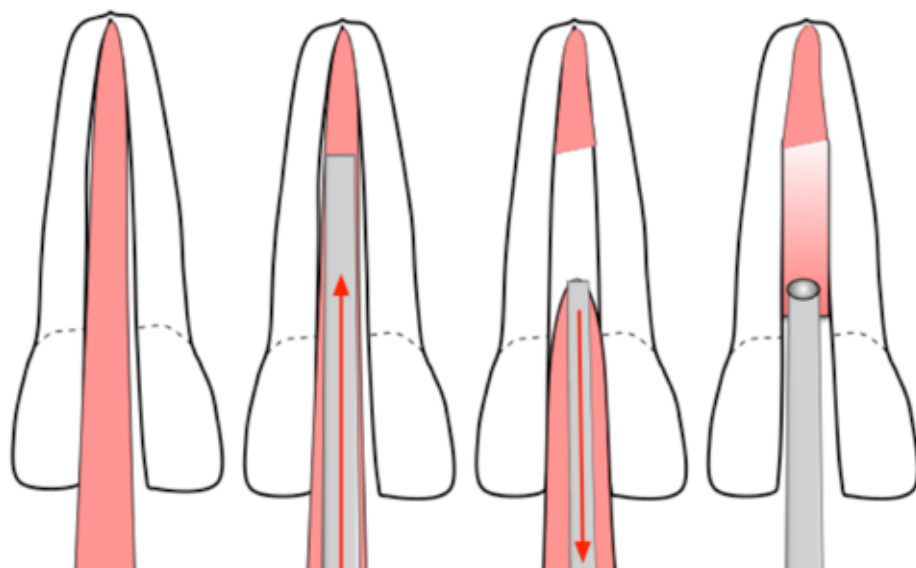
### Carrier-based thermoplasticized technique<sup>18</sup> (*Thermafil, Successfil and Simplifill*)

Warm GP or 'Resilon'-coated plastic core carriers (more recently, gutta-percha core carriers – Dentsply) are inserted into the canal to the working length. In practice a blank core must be inserted into the canal before obturation to verify length, taper and fit. Following this, the canal should be lightly coated with sealer and the point is placed in an oven to heat before being carefully but quickly inserted within the canal (Figures 9 and 10). This technique is fast and obturates the canal well, but true length control is lacking and there is a risk of extrusion of both sealer and GP. It is also easy for the GP to 'strip' off from the carrier before being fully inserted, leaving an inadequate fill with voids and contact of the carrier with the root wall rather than sealer and GP.

Removal of cores can be difficult in retreatment cases or when a post is intended. Though specific burs are available for removing the cores, these can be tricky to use. Plastic cores are being superseded by cross-linked GP cores (Figure 11 *GuttaCore*, Dentsply, Tulsa, USA) and may negate some



**Figure 6.** Sizing guides (Dentsply, Tulsa, USA) are an inexpensive method of confirming the size of the GP point selected. Simply insert the GP into the corresponding hole. If the GP point is smaller than the ISO size it will protrude beyond the guide and can be simply cut to length with a scalpel. If the point is too large select another point.



**Figure 7.** The 'continuous wave' technique: following placement of the master cone, a heated plugger is inserted into the canal to sever the coronal GP and warm the apical GP. Pluggers are then used to compact the remaining GP apically. Following this the canal system is back-filled with plasticized GP.

of the problems described, but as yet there is a paucity of clinical data to confirm or refute this.


**Thermomechanical compaction<sup>19</sup> (McSpadden Compactor)**

A master cone coated with sealer is fitted to working length and is compacted

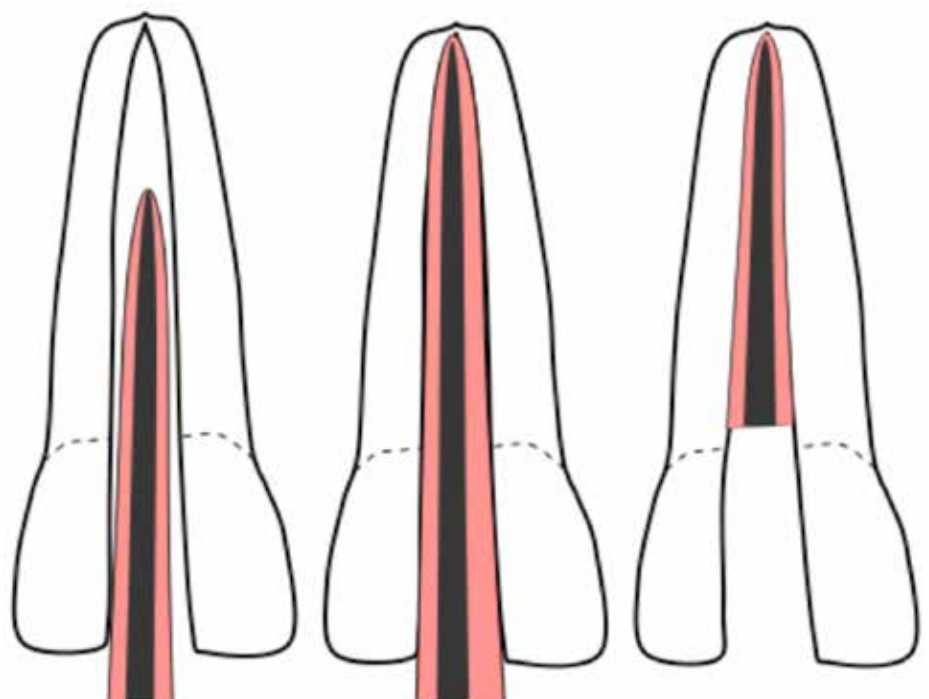
by hand spreader and then with a rotary instrument running between 5,000 and 10,000 rpm. The rotary instrument is pre-coated with pre-warmed gutta-percha which, owing to its more fluid state, and also due to friction of the compactor and the canal wall, vectors the GP and sealer into the canal and all intricacies.

**Plasticized GP injection techniques**

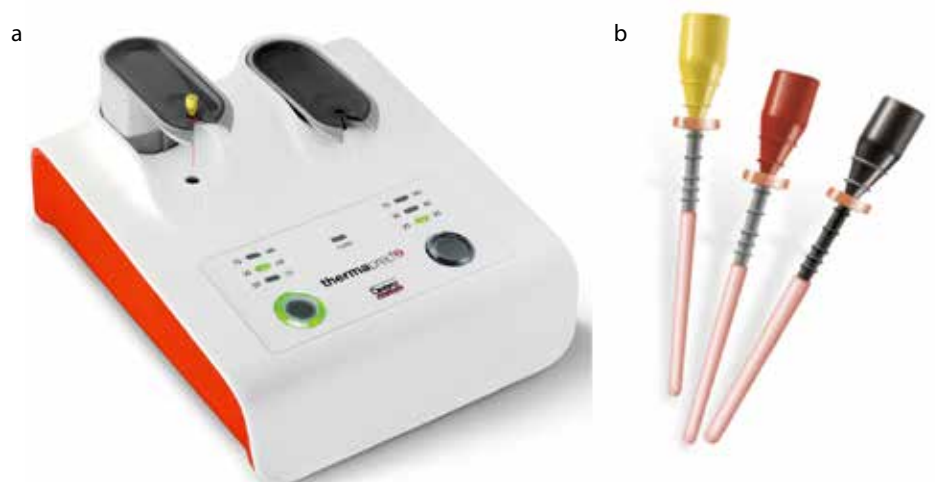
Plastic techniques have the theoretical benefit of improving obturation as the material can flow within the canal space. Injection techniques alone without a cold cone or plug of GP at the apical constriction are not advised due to difficulties in length control. Although GP is relatively



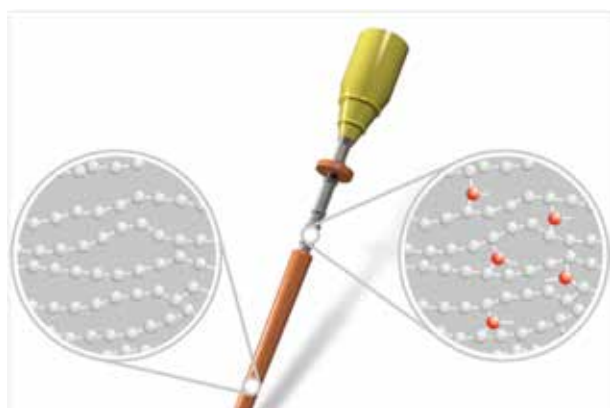
**Figure 8. (a)** The System B and **(b)** Obtura combination used with 'continuous wave' obturation. The former is the heated pluggers system and the latter a device for heating and extruding plasticized GP.



**Figure 9.** Carrier-based systems: the GP coated carrier is warmed in a dedicated oven and swiftly inserted into the prepared and sealer-lined canal. The carrier is then severed before final restoration.



**Figure 10. (a)** The oven for heating the GP when using a carrier technique. **(b)** GP points with plastic carrier clearly visible.



**Figure 11.** *GuttaCore* (Dentsply, Tulsa, USA): the core of the carrier is also gutta-percha. This should enable improved obturation and ease of retreatment.



**Figure 12.** The *Obtura III* system (Obtura Spartan Endodontics, CO, USA): GP cartridges are inserted into the 'gun' and heated to 200 °C. It can then be injected into the canal.

biocompatible, the clinician should take care to prevent extrusions, especially into the sinus or ID canal.<sup>20</sup>

**1. Heated systems<sup>21</sup> (*Obtura III, Ultrafill 3D, Calamus, Elements, HotShot*)**

The core material is heated outside the mouth and injected into the canal system using the commercially available

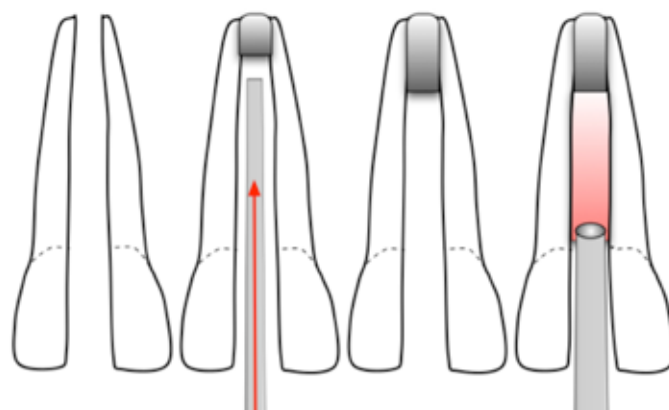
devices. A master cone is not usually used and the canal should be coated with sealer before injection (Figure 12).

**2. Cold systems (*GuttaFlow*)**

Triturated GP is mixed with resin sealer (di-polyvinyl siloxane) in an amalgamator to form a cold flowable matrix. The matrix is injected into the canal and a single master cone is placed to the working length. The material provides a working time of 15 minutes and sets within 30 minutes. The use of a master cone within the GP sealer is advocated.

**3. Chemoplastized compaction**

The technique involves softening the tip of the master GP cone using chloroform, eucalyptol or xylol and fitting it into the canal. The mass is then compacted using a lateral technique. Though this technique exhibits shrinkage and has been replaced by other techniques, these authors believe that there is still a place for customization of points to improve the apical fit of GP. The master point should be dipped in solvent (30 seconds for eucalyptus oil) and then inserted into the canal; it will form a custom impression of the apical region. The point is then removed, and sealer applied before being resealed with exactly the same path of entry and position.



**Figure 13.** Apical barrier technique: where canal diameter precludes adequate sealing with conventional techniques MTA is placed using pre-measured pluggers in increments apically. Intra-operative radiographs should be taken to confirm that the MTA has been placed optimally before further increments are placed. Once 3–5 mm has been placed the canal is backfilled with plasticized GP.

**4. Pastes**

The pastes are injected into the prepared canal as the final root-filling material, usually in the absence of a cone. Examples, such as *Traitement SPAD* and *Endomethasone* have been used in the past. These have fallen out of favour, principally because the agents are very toxic if extruded and also due to problems which include; porosities resulting in poor seal, inadvertent extrusion and difficulties presented for retreatment.

**Apical barrier<sup>22</sup>**

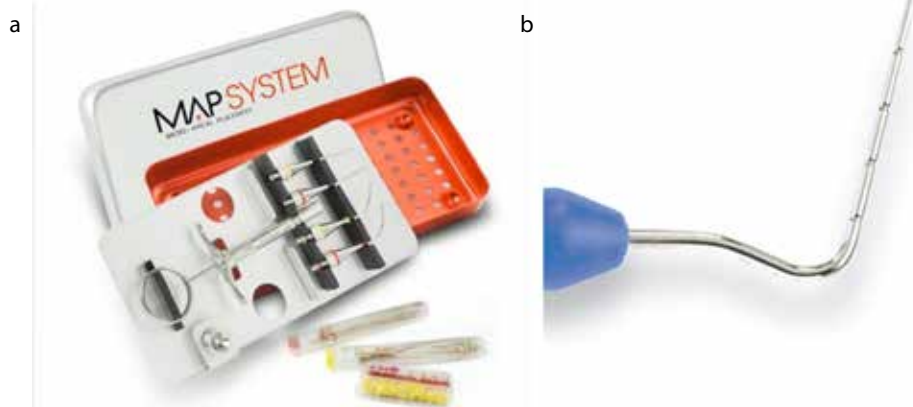
An apical barrier technique plays an important role when obturating teeth with open apices. Mineral trioxide aggregate (MTA) is the material of choice. MTA is compacted by hand to fill the apical 3–5 mm of the canal. Initially it is a good idea to create a 1–2 mm plug first at the apex and then check this radiographically. Once this has been placed satisfactorily, further MTA can be placed coronal to this. A total of 3–5 mm of MTA should be placed in increments with either hand instruments or micro pluggers. This is often only possible in wider, straighter canals. The remainder of the canal system can then be filled with an injection technique (Figures 13 and 14).

There are risks and benefits to all systems (Table 5). We recommend operators familiarize themselves with multiple systems:



Method	Example	Pros	Cons
Single point	Matched greater taper preparation and GP point	Simple Fast Inexpensive	Inadequate fill Reliance on sealers
Cold lateral compaction	ISO GP and accessory points	Commonly taught Good for canals without standardized tapers Good apical control of GP possible	Compaction of GP only Voids may remain Not good for irregular-shaped canals Technique sensitive
Warm vertical condensation	Schilder technique Continuous wave condensation	Good 3-dimensional obturation	Technique sensitive Costly equipment Risk of apical extrusion
Thermomechanical techniques	McSpadden technique	Good 3-dimensional obturation	Risk of apical extrusion Risk instrument separation
Carrier-based systems	<i>Thermafil</i> <i>Guttacore</i>	Single point technique Good 3-dimensional obturation Simple and fast	GP may strip from carrier Technique sensitive Hard to remove Risk of apical extrusion
Plastic techniques	<i>Obtura</i> <i>Guttaflow</i>	Good 3-dimensional obturation	Risk of apical extrusion Shrinkage of GP with setting/cooling May present difficulties with removal depending upon material
Apical barrier	MTA	Good apical control of material Bioactive Allows controlled back fill with alternative techniques	Expensive Hard to remove Technique sensitive May require microscope

**Table 5.** Advantages and disadvantages of differing obturation methods.



**Figure 14.** (a) The MAPSYSTEM (Dentsply, Tulsa, USA) for apical placement and (b) plugger used for apical compaction of MTA.

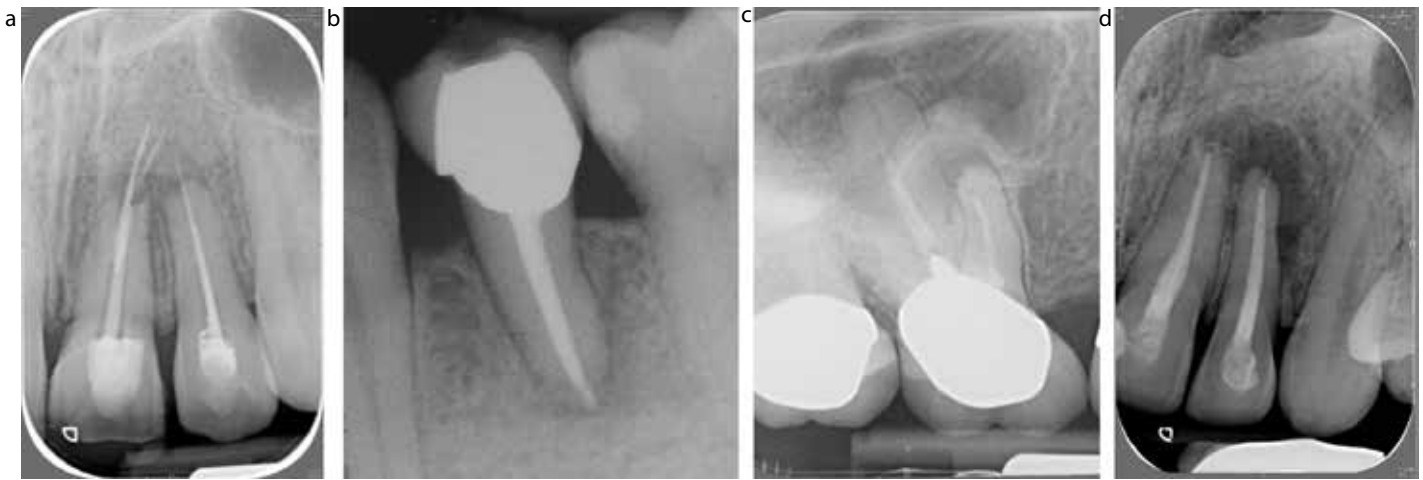this affords the ability to adapt to the clinical scenario presented. Furthermore, it is possible to 'pick and mix' techniques. A classic

example of such may be in the case of upper incisors, where the canal is wide and greater taper cones do not fit 'snuggly' following

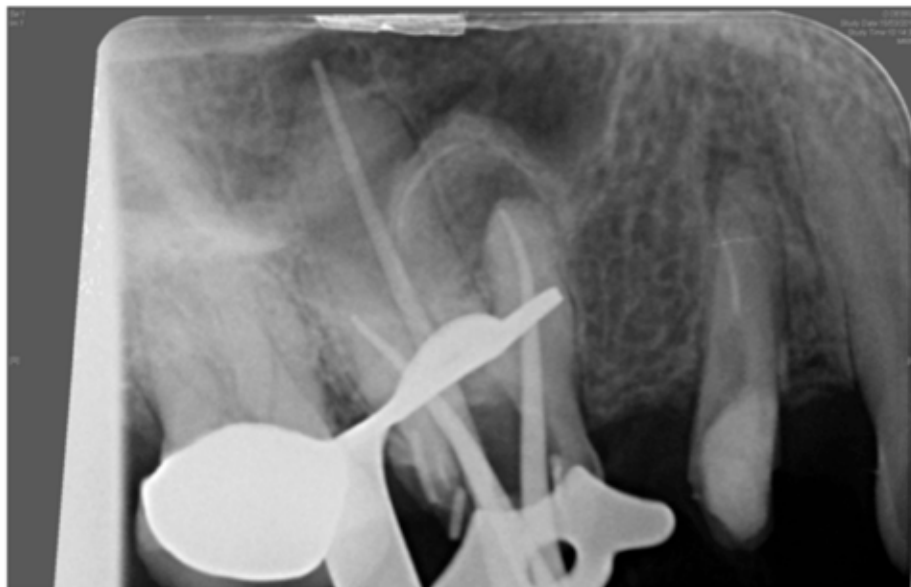preparation. The operator may choose cold lateral compaction to obturate the apical 50% followed by a 'continuous wave technique', which can soften the laterally condensed GP, giving a more homogenized fill, before adding further GP more coronally.

### Overfill, overextension and underfill

Recent evidence suggests that, for every mm a canal is underfilled, the success of the root treatment drops by 12%. If the GP is over extended, the success drops by 62%.<sup>23</sup> This supports the adage that it is preferable to be short of the apex than long, but alerts the clinician to the importance of attempting to shape and obturate to within just 2 mm of the anatomical apex. Assuming apical patency and adequate working length was achieved, three possible scenarios may result that do



**Figure 15.** (a) Overextension. (b) Overfill. (c, d) Underfill.



**Figure 16.** A cone fit radiograph can correct extension before obturation. In this case the palatal canal has been over prepared and the disto-buccal canal underprepared.

not favour a good outcome. These are as follows<sup>16,24</sup> (Figure 15).

**1. Overextension: GP extends grossly beyond the apex**

This reflects both poor apical fit of the cone and poor obturation technique. These cases may fail and retrieval of overextended GP is not easy. A carefully rotated Hedstrom file into the GP may be sufficient to pull out the entire point during retreatment, but often these cases can only be managed surgically. If the working length (WL) measurement is 22 mm, and the GP fits snugly

at 27 mm, the operator should be alerted to the possibility of an error somewhere!

**2. Overfill: GP is well condensed but radiographically beyond the apex**

This may be a reflection of over-zealous apical preparation and loss of apical architecture but can occur when there is an immature apex or external inflammatory resorption.<sup>25</sup> There is evidence that a more aggressive apical preparation may have a more favourable healing but the clinician must always aim to remain within the canal and preserve the apical constriction.<sup>26</sup> If

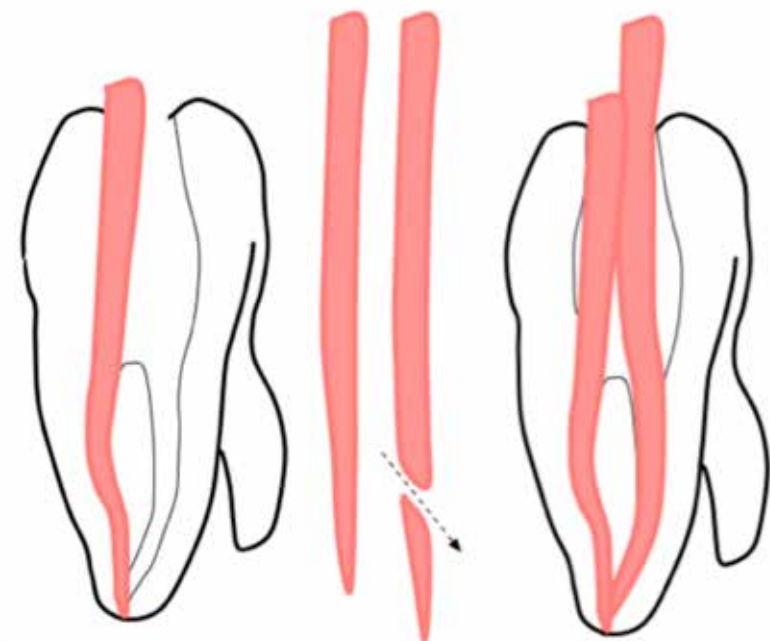
there is pre-operative radiographic evidence of changes in the periapical anatomy, or anticipated difficulty in controlling obturation, the clinician must consider an alternative technique, such as the use of MTA as described above.

**3. Underfill/Underextension: GP is short of the apex with or without voids**

This is indicative that the canal space has not been adequately shaped and/or cleaned, as such bacterial colonies may remain within the root canal system and disease can persist.

**Preventing extension problems**

- Consider using instrumentation techniques that allow controlled obturation with matched greater taper continuous or variable taper points.
- Meticulous length control is important during instrumentation. Instruments should not be forced apically and rotary instruments should not be used for more than 2–3 ‘pecks’ at the WL to prevent overpreparation or zipping.
- If in doubt always verify the WL. The use of a cone-fit radiograph with the master GP in place is invaluable if uncertain or a WL radiograph was not taken in advance (Figure 16).
- If there is a discrepancy with WL and the length the GP fits to, do not obturate.
- Use plasticized techniques with caution and take extra precaution when working in close proximity to significant anatomical structures.



**Figure 17.** When canals coalesce, seat one point to WL and remove the apical GP from the second point until it abuts the first point at the desired WL.

■ If the GP does not seat to WL it may be that two canals coalesce (classically mesial roots of lower molars). To ensure adequate obturation of both canals, fill the first. Cut the tip from the GP of the second canal with a scalpel until the GP abuts the first GP point at the correct WL (Figure 17).

## Conclusions

There is minimal evidence to support the use of one method of obturation over another. All techniques have advantages and disadvantages. Decision-making should be based upon the clinical scenario, not dogma. As such, having a broad knowledge of the options helps the clinician choose the optimal technique for the tooth being treated.

## References

1. Wu M-K, Fan B, Wesselink PR. Leakage along apical root fillings in curved root canals. Part I: effects of apical transportation on seal of root fillings. *J Endod* 2000; **26**(4): 210–216.
2. Ng YL, Mann V, Rahbaran S *et al.* Outcome of primary root canal treatment: systematic review of the literature – Part 2. Influence of clinical factors. *Int Endod J* 2008; **41**(1): 6–31.
3. WU MK, Wesselink P. Endodontic leakage studies reconsidered. Part I. Methodology, application and relevance. *Int Endod J* 1993; **26**(1): 37–43.
4. Grossman LI, Oliet S, Carlos E *et al.* *Endodontic Practice*. The University of Michigan: Lea & Febiger, 1988.
5. Biggs SG, Knowles KI, Ibarrola JL *et al.* An *in vitro* assessment of the sealing ability of resilon/epiphany using fluid filtration. *J Endod* 2006; **32**(8): 759–761.
6. Smartseal. *Smartseal: How it works*. 2012 [13 Jan 2015]. Available from: [www.smart-seal.co.uk/how-it-works/](http://www.smart-seal.co.uk/how-it-works/)
7. Tay FR, Pashley DH. Monoblocks in root canals: a hypothetical or a tangible goal. *J Endod* 2007; **33**(4): 391–398.
8. Aqrabawi J. Outcome of endodontic treatment of teeth filled using lateral condensation versus vertical compaction (Schilder's technique). *J Contemp Dent Pract* 2006; **7**(1): 17–24.
9. Ng YL, Mann V, Rahbaran S *et al.* Outcome of primary root canal treatment: systematic review of the literature – Part 1. Effects of study characteristics on probability of success. *Int Endod J* 2007; **40**(12): 921–939.
10. de Chevigny C, Dao T, Basrani B *et al.* Treatment outcome in endodontics: the Toronto Study – Phase 4: initial treatment. *J Endod* 2008; **34**: 258–263.
11. Peng L, Ye L, Tan H *et al.* Outcome of root canal obturation by warm gutta-percha versus cold lateral condensation: a meta-analysis. *J Endod* 2007; **33**(2): 106–109.
12. Whitworth J. Methods of filling root canals: principles and practices. *Endod Topics* 2005; **12**(1): 2–24.
13. Gordon M, Love R, Chandler N. An evaluation of .06 tapered gutta-percha cones for filling of .06 taper prepared curved root canals. *Int Endod J* 2005; **38**(2): 87–96.
14. Meister Jr F, Lommel TJ, Gerstein H. Diagnosis and possible causes of vertical root fractures. *Oral Surg Oral Med Oral Pathol* 1980; **49**(3): 243–253.
15. Allison DA, Weber CR, Walton RE. The influence of the method of canal preparation on the quality of apical and coronal obturation. *J Endod* 1979; **5**(10): 298–304.
16. Schilder H. Filling root canals in three dimensions. *Dent Clin North Am* 1967; **11**(7): 723–744.
17. Buchanan L. The continuous wave of condensation technique: a convergence of conceptual and procedural advances in obturation. *Dent Today* 1994; **13**(10): 80–85.
18. Johnson W. A new gutta-percha technique. *J Endod* 1978; **4**(6): 184–188.
19. McSpadden J. *Self Study Course for the Thematic Condensation of Gutta-Percha*. Toledo, Ohio: Ransom & Randolph, 1980.
20. Gluskin AH. Mishaps and serious complications in endodontic obturation. *Endod Topics* 2005; **12**(1): 52–70.
21. Yee FS, Marlin J, Arlen Krakow A *et al.* Three-dimensional obturation of the root canal using injection-molded, thermoplasticized dental gutta-percha. *J Endod* 1977; **3**(5): 168–174.
22. Torabinejad M, Chivian N. Clinical applications of mineral trioxide aggregate. *J Endod* 1999; **25**(3): 197–205.
23. Ng YL, Gulabivala K, Mann V. A prospective study of the factors affecting outcomes of non-surgical root canal treatment: part 1 periapical health. *Int Endod J* 2011; **44**: 583–609.
24. Gluskin AH. Anatomy of an overfill: a reflection on the process. *Endod Topics* 2007; **16**(1): 64–81.
25. Darcey J, Qualtrough A. Resorption: part 1. Pathology, classification and aetiology. *Br Dent J* 2013; **214**(9): 439–451.
26. Schilder H. Cleaning and shaping the root canal. *Dent Clin North Am* 1974; **18**: 269–296.